

Engaging Junior Health Professionals Through Links

Oliver Johnson
6th Year Medical Student, KCL
Medsin-UK

Barriers to trainee involvement

- Preparation & Training
- Supervision
- Sustainability



Trainees in Somaliland



Simon Little, Nathalie Cronin and Alexander Finlayson with Somali colleagues



Medicine Africa Teaching Website

Welcome! - Medicine Africa

http://www.medicinafrica.com/user_menu.php?userid=4

Most Visited Getting Started Latest Headlines Dana-Farber/Harvar... Apple Amazon eBay Yahoo! News

medicinafrica.com Home alexanderfinlayson@gmail.com London Time: 24 Nov 2009 / 01:05 Logout

What would you like to do?

- Organise Meeting
- Add Medical Case
- Add Images
- Join a Group

Meeting Invitations

- General Medicine Intern Teaching - Respiratory hide

Recent Activity

- Dr Mohamed Mosa Hasan** saved the meeting [surgical case discussion](#) to favorites. 3d 12h ago
- Dr Mohamed Mosa Hasan** added new profile images 3d 12h ago
- Seema Biswas** saved the meeting [TB abdomen](#) to favorites. 3d 16h ago

New meeting:

- TB abdomen** by **Seema Biswas**
Are you there? Can you upload your cases? I have been online since 8am UK time. If you want some teaching I am available again at 2 pm UK time
ARE YOU THERE NOW?
2d 16h ago [save to favorites](#)

New meeting:

- 14 months old boy with neck swelling for 1 month** by **mohamed hasan**
14 months old from G/Ilbax presented with nodules on the anterior chest and the neck with generalized lymphadenopathy for 1 month. He has also cough, fever, wt. loss and night sweats.
Medical Cases: 14 months old boy with neck swelling for 1 month ,
This meeting will start in 4d 19h [save to favorites](#)

People you might know

- Dragos Tanasie
- rebecca syed
- xaamud axmed
- Ruthanne Millen
- Frank Post

Featured Medical Case: [Staphylococcus Aureus Prostatic Abscess Complicated By Infective Endocarditis](#)

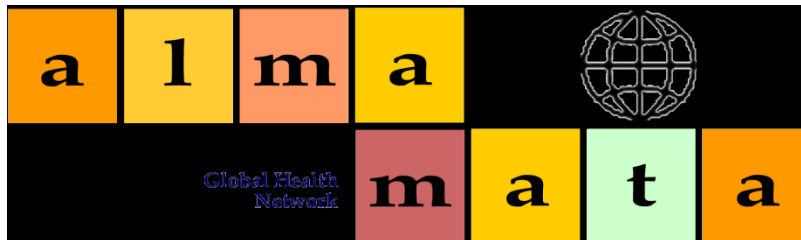
Author: M. Auron, M.D. Department of Hospital Medicine, Cleveland Clinic
Reviewer: V. Dimov, M.D., Department of Hospital Medicine, Cleveland Clinic
A 50 yo male with type 2 diabetes mellitus (recent HbA1c 7.5%) was admitted with complaints of dysuria and non-specific abdominal pain for 1 week, accompanied by malai...

Featured Medical Case Video: [Multimedia Case \(ignore this case\)](#)

A national hub for trainee involvement in links



- National Student Organisation
- Volunteering, Advocacy, Education
- 30 branches, 3000 active members



- National Junior Health Professionals Group
- Network and Career Advocacy